

04.03.2024

ANDREI VALERIU, 74 ani

Acuze: - caligă vizuală  
- polihidurie nocturnă 3-4x/noaptea  
- diaree

Ex de ic: lărgire aendă redusă, bimanuală absent bilateral  
OGE - aspect normal

Exe: Ambliopie - indice paracentral  
punctat, fovea ciliată SPC.  
Veziculi veziculare cu multiple di-  
verticuli, mare 3 cm.

Prostată: 69/72/78 mm  
Vol = 194 cc  
RU: 300 cc

Diag: HBP - AVODART + URORECT  
Retroscrotală incompletă de nivel SUTUVERT  
APP: 2017: HBP - ex AP: HBP

12.2022: PSA = 5.74, rPSA = 1.11  
11.2023: PSA = 11.9, rPSA = 1.6

Rec: 1. PSA, free PSA

2. Medicatie:  
AVODART 1 cp/zi - până - 6 luni  
UROREC 1 cp/zi - până - 6 luni  
SUTUVERT 1 cp/zi - 6 luni

+/- IRM prostată

3. Control + rezidua vezical

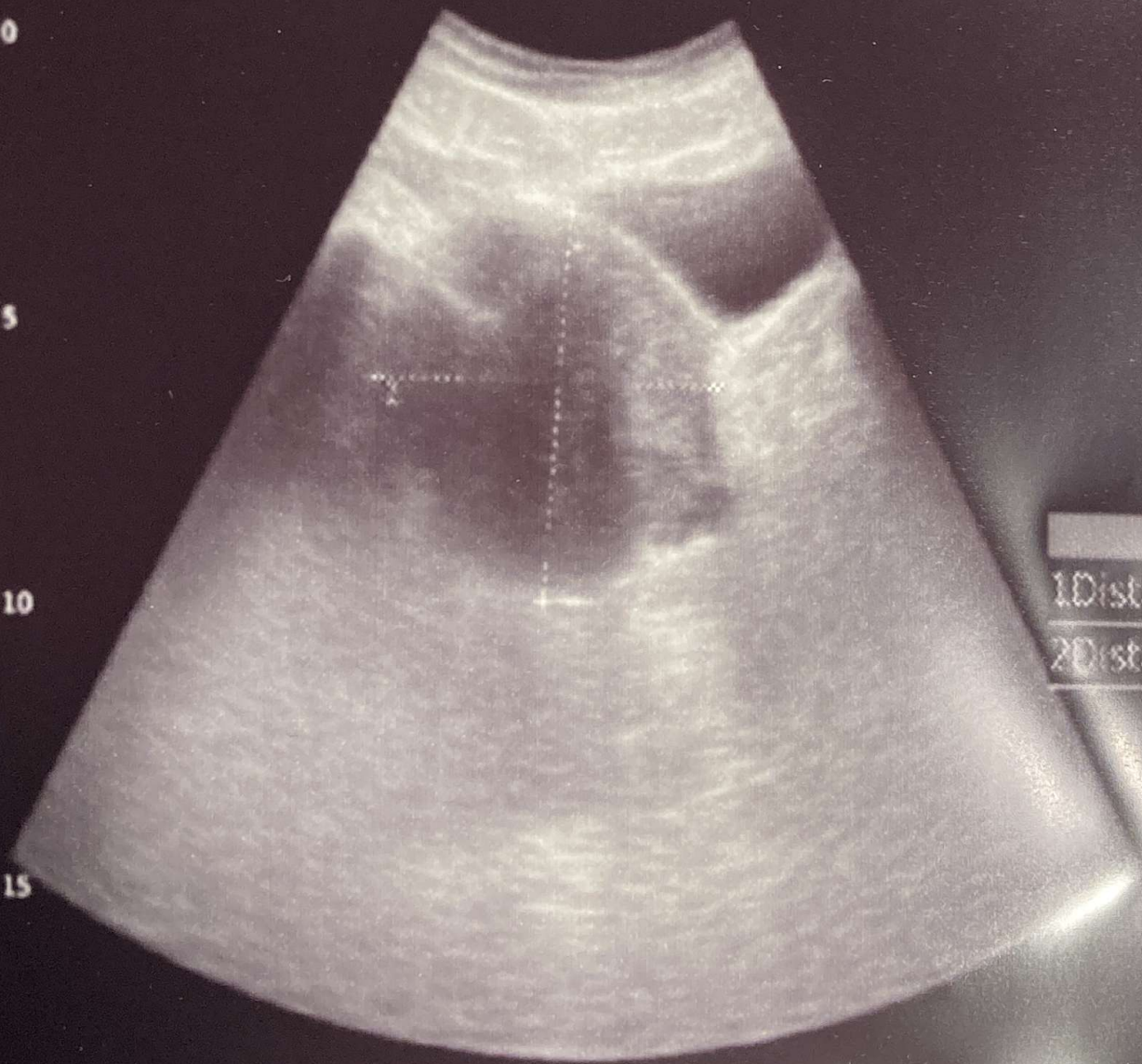
Conf. Dr. Răzvan PETCA  
medic primar Urolog  
cod: 059953

Slim Healthy Center  
ABD

MI 0.80 TIS:0.10  
D3C60L/H4.5M

01-01-2000  
03:26:30

- 0  
- 5  
- 10  
- 15



FPS: 30  
GN: 100  
PWR: 100 %  
FRQ: 4.5M  
DN: 120  
D: 18.0 cm  
PHI: On  
Zoom: Sup

1 Distance 69.53 mm  
2 Distance 72.95 mm

Slim Healthy Center

MI 0.80 TIS:0.10

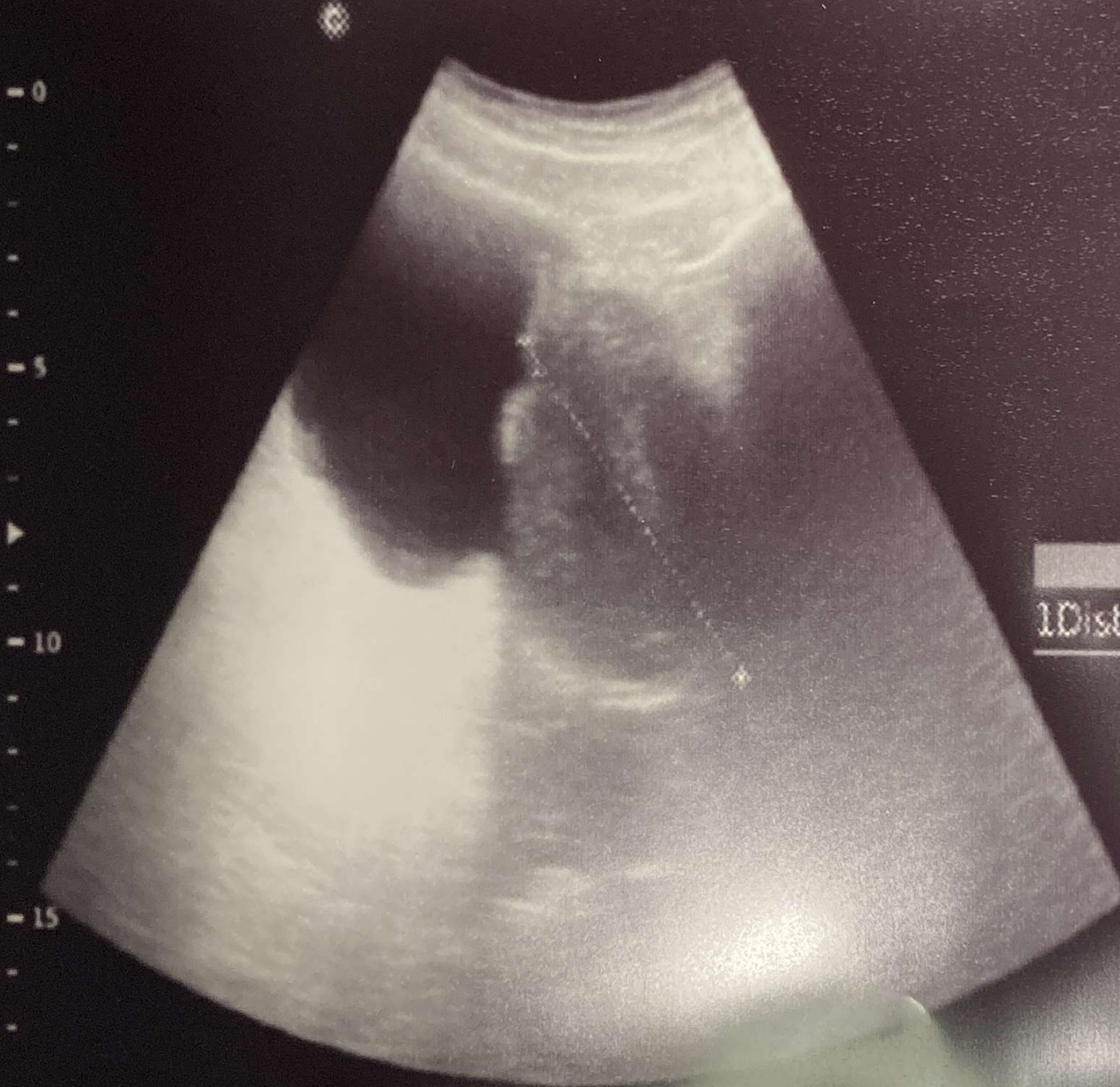
01-01-2000

ABD

D3C60L/H4.5M

03:26:55

FPS: 30  
GM: 100  
PWR: 100 %  
FRQ: H4.5M  
DM: 120  
D: 18.0 cm  
FHI: On  
X-con: Sup



1 Distance 78.10 mm

Slim Healthy Center  
ABD

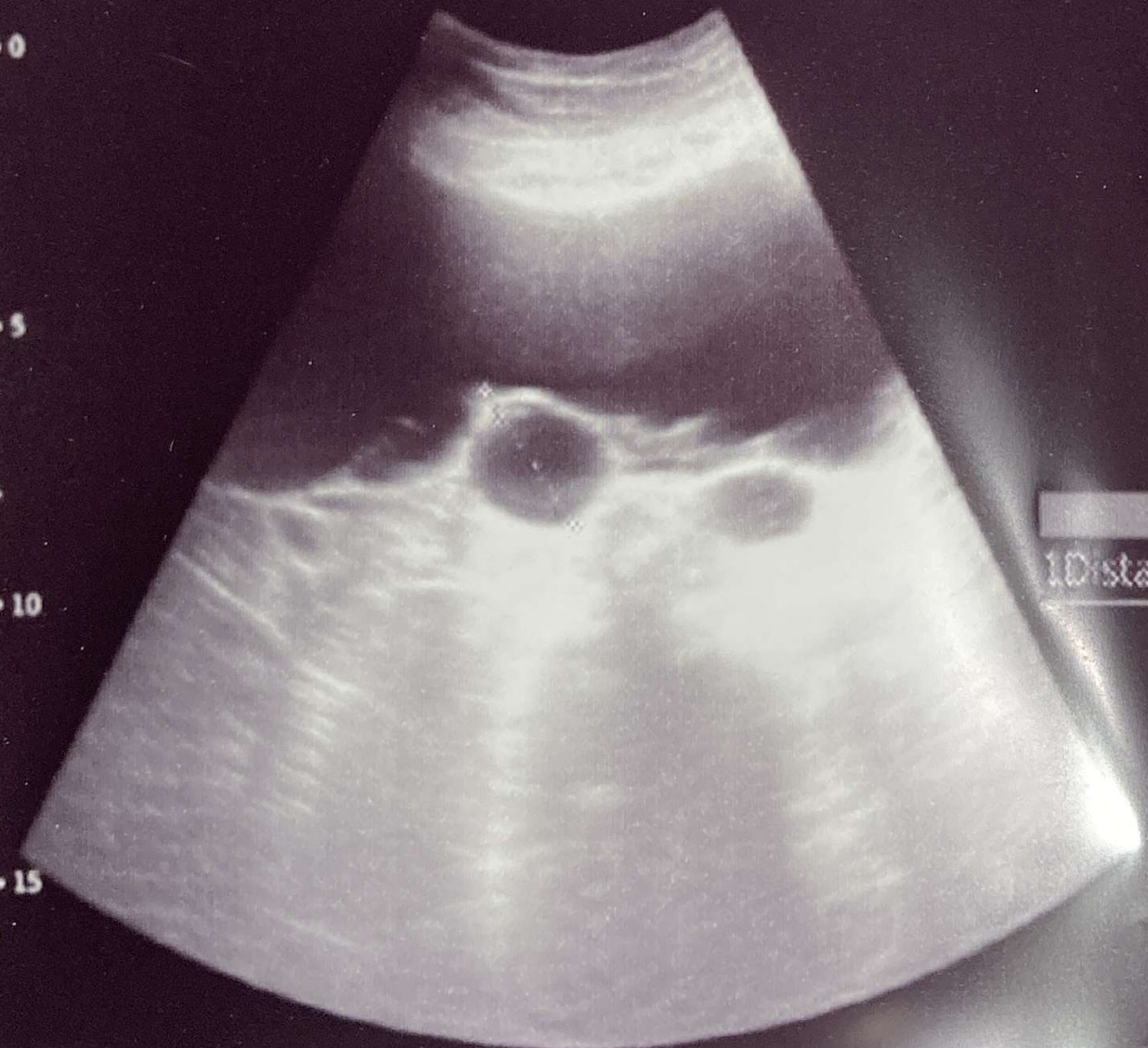
MI: 0.80 TIS: 0.10  
D3C60L/H4.5M

01-01-2000  
03:25:48

0  
5  
10  
15

FPS: 30  
GM: 100  
PWR: 100 %  
FRQ: H4.5M  
DN: 120  
D: 18.0 cm  
FHI: On  
X-con: Sup

Distance 31.08 mm



Slim Healthy Center

ABD

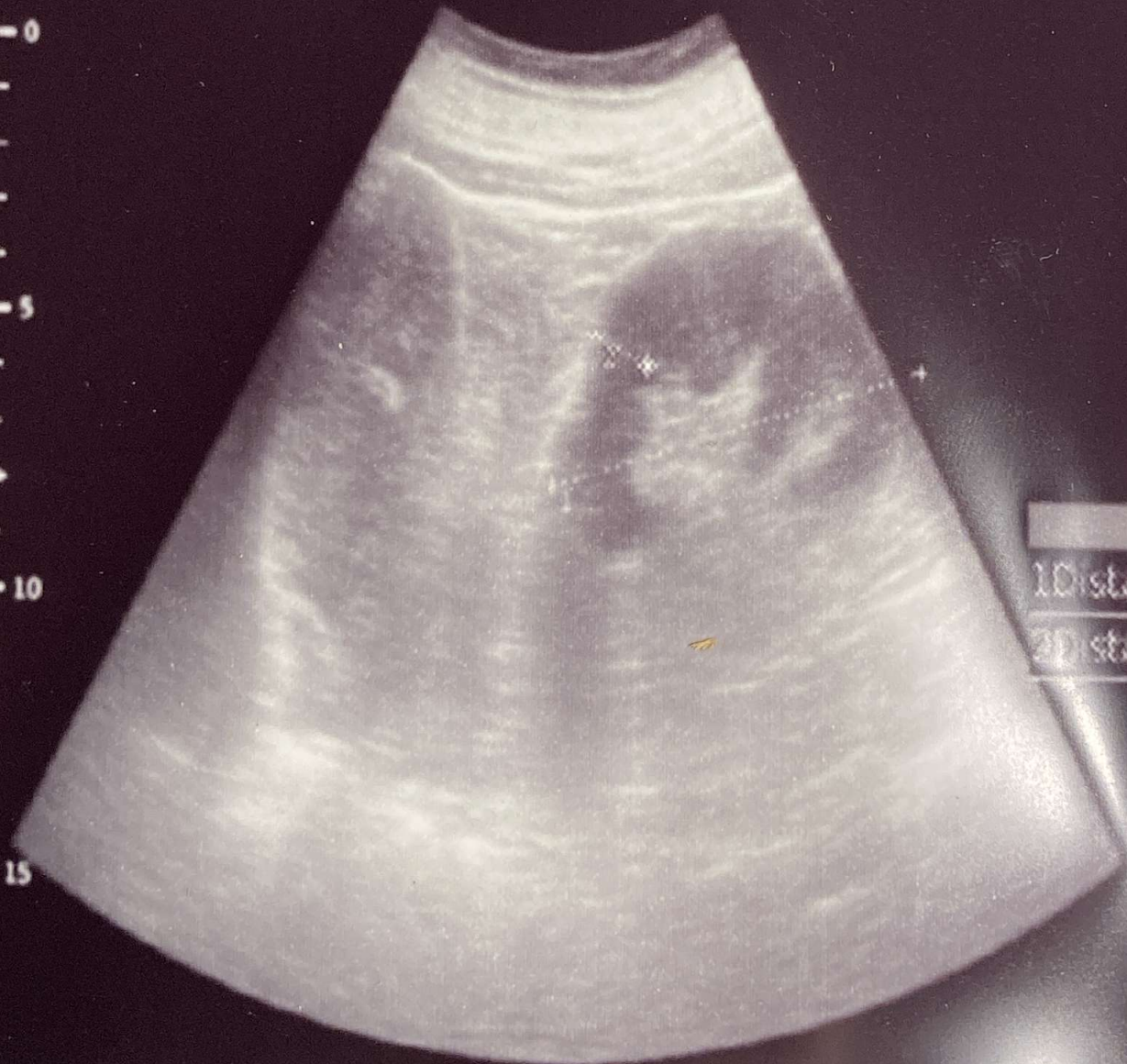
MI:0.80 TIS:0.10

D3C60L/H4.5M

01-01-2000

03:25:23

-0  
-5  
-10  
-15



FPS: 30  
GN: 100  
PWR: 100 %  
FRQ: H4.5M  
DN: 120  
D: 18.0 cm  
FHI: On  
X-con:Sup

1 Distance 85.13 mm

2 Distance 12.51 mm

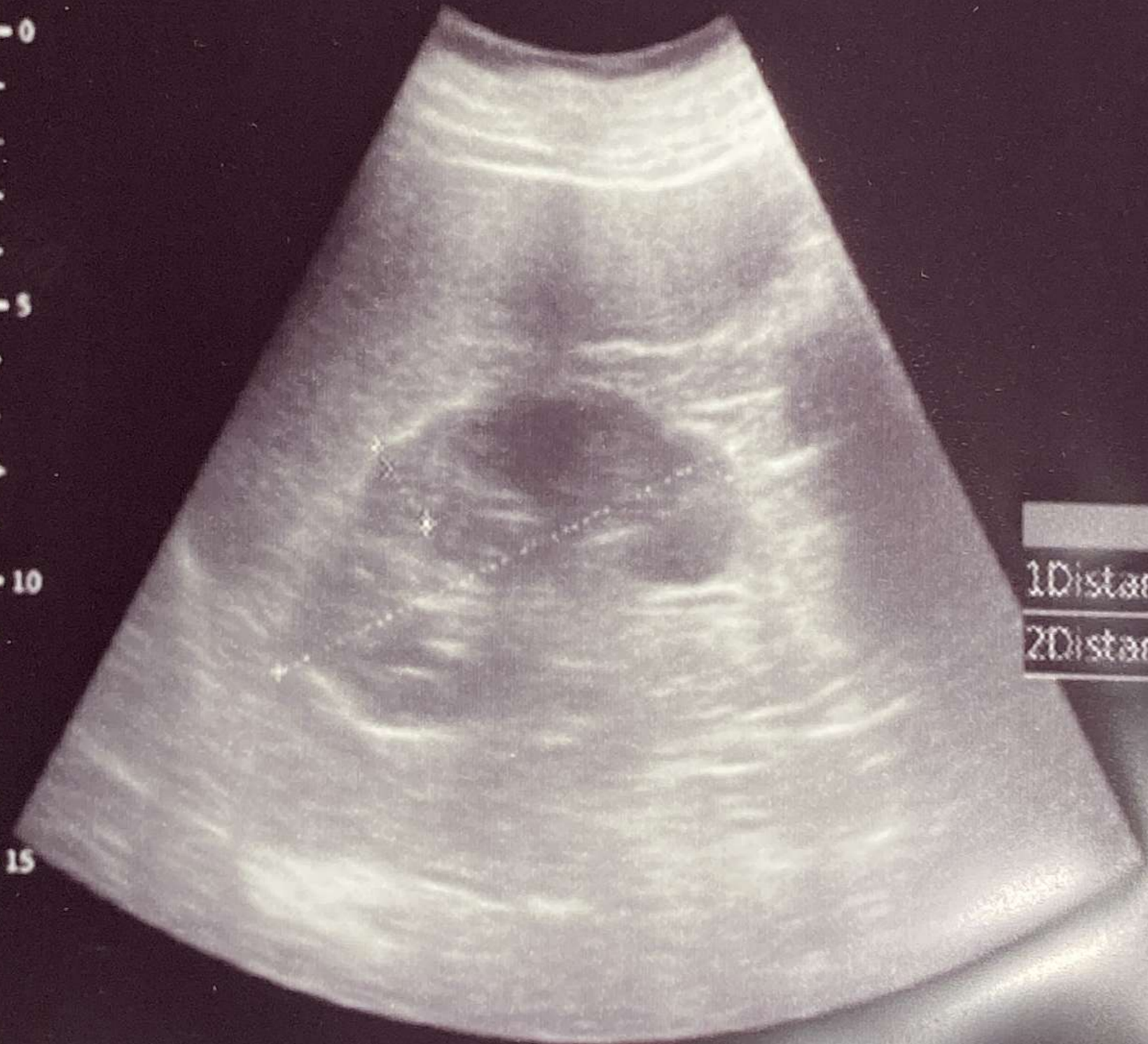
Slim Healthy Center  
ABD

MI:0.80 TIS:0.10  
D3C60L/H4.5M

01-01-2000  
03.24.15

FPS: 30  
GN: 100  
PWR: 100 %  
FRQ: H4.5M  
DM: 120  
D: 18.0 cm  
FHI: On  
X-con:Sup

-0  
-5  
-10  
-15



1 Distance 106.37 mm  
2 Distance 17.85 mm